



2025

**KARNATAKA RADIOLOGY EDUCATION PROGRAM**

# CHEIF COMPLAINTS

## Patient Profile

Name: ABC

Age: 18 years

Sex: Male

Presenting Complaint: Sudden severe headache and vomiting

## History of Presenting Illness:

An 18-year-old previously healthy male presented to the emergency department with a sudden onset of "worst headache of her life" that began 2 hours prior to admission. The headache was abrupt, severe, and diffuse, associated with nausea and vomiting

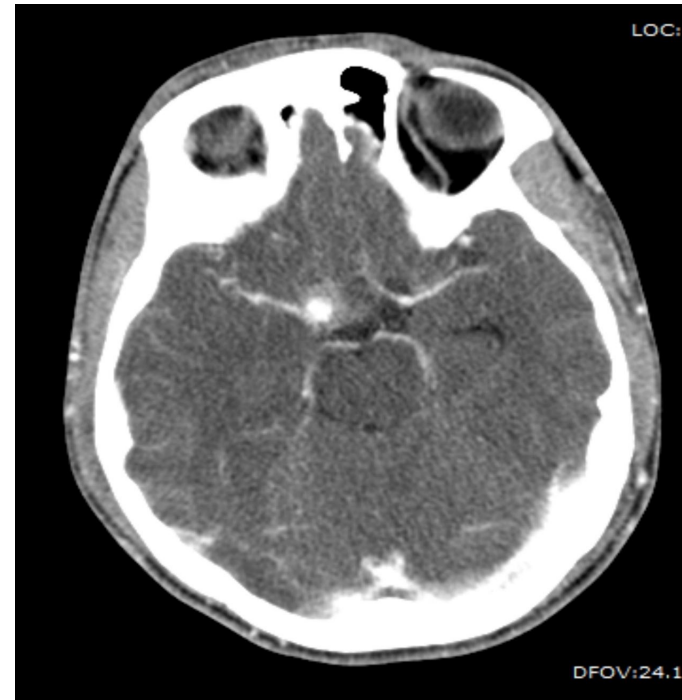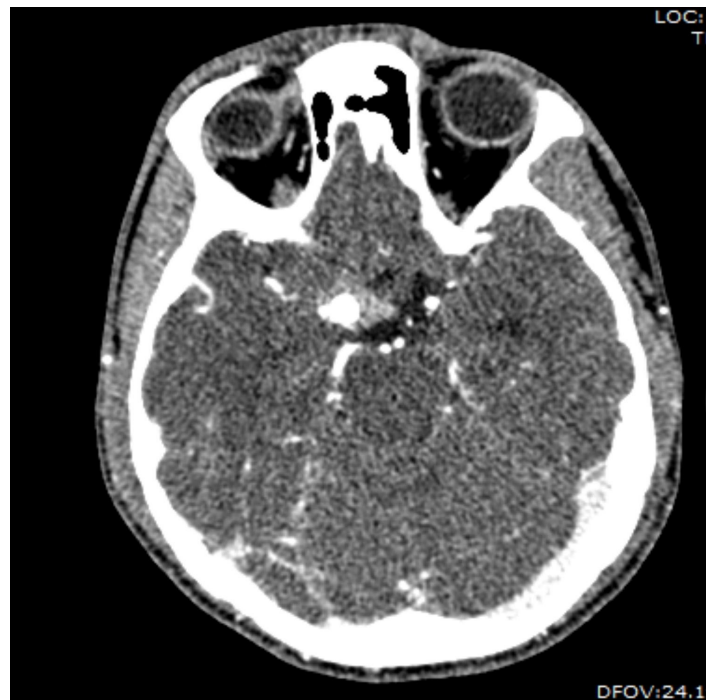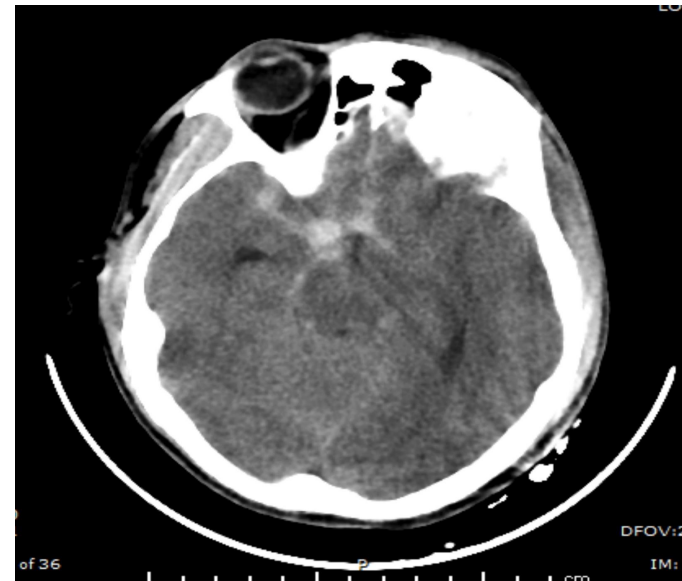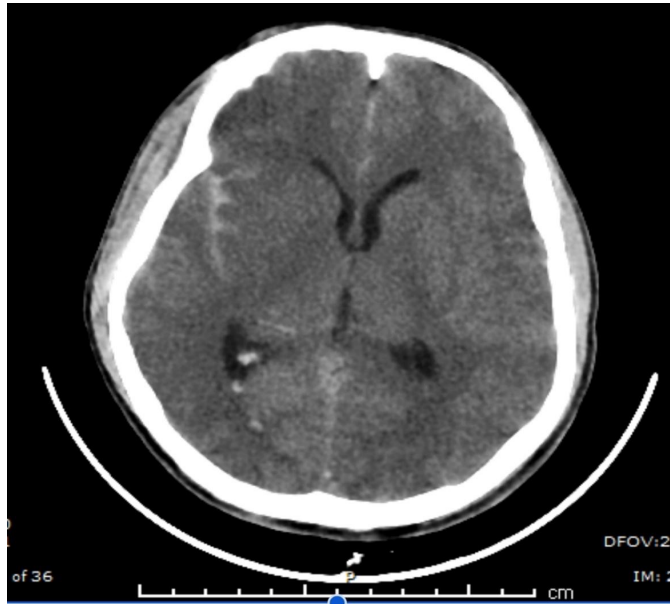
Past Medical History:

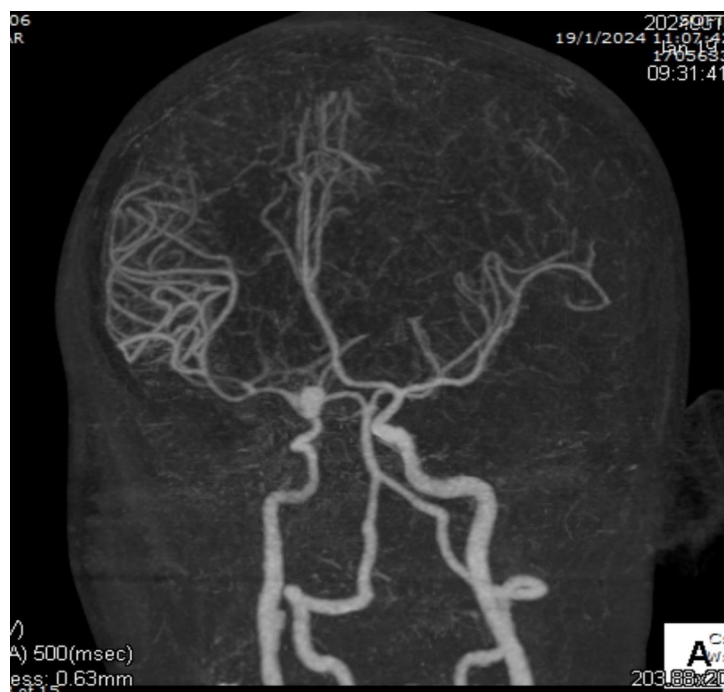
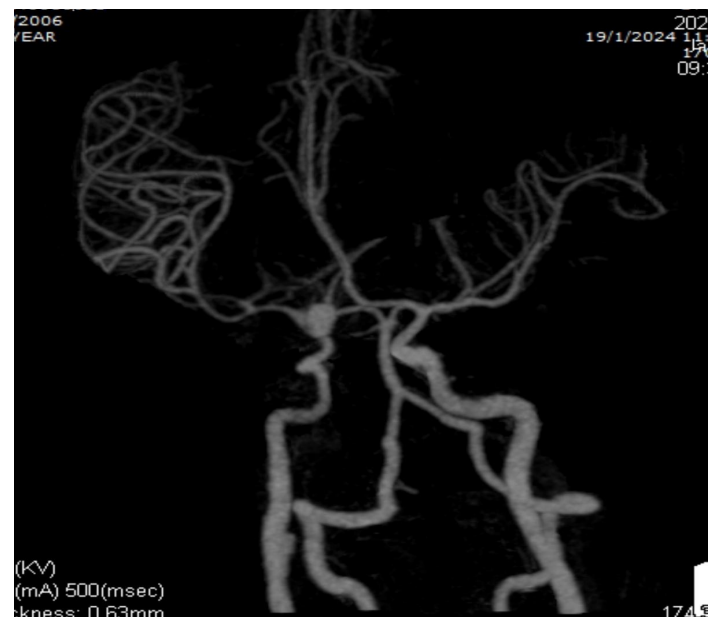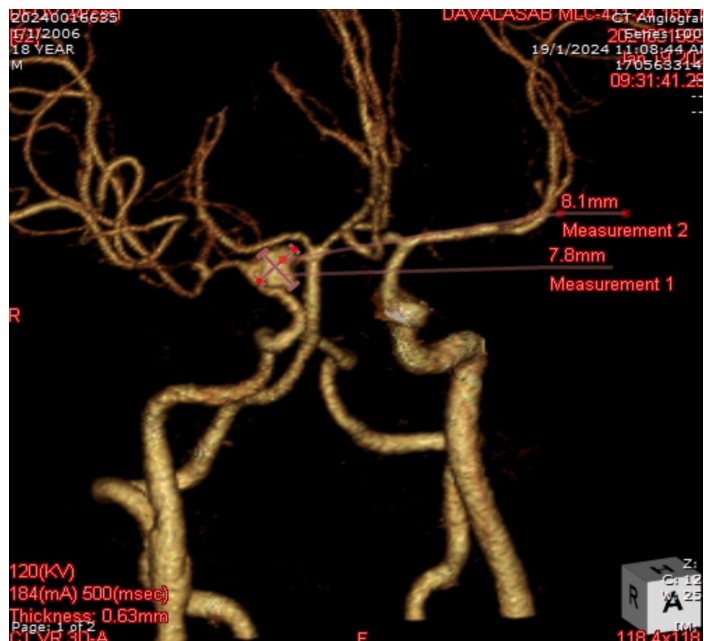No known chronic illnesses

No previous similar episodes

No history of seizures or hypertension

# CT





# CT FINDINGS

- SAH noted along right sylvian fissure ,ambient cistern and interhemispheric cistern.
- Focal outpouching noted arising from right ICA at the bifurcation into MCA and ACA. It measures ~ 8x7.6mm-->**Berry aneurysm.**

**Impression: BERRY ANEURYSM OF RIGHT ICA AT THE BIFURCATION INTO MCA AND ACA.**

# MENTORS

**Dr.G.C.Patil**

PROFESSOR

DEPT OF RADIO DIAGNOSIS

KMCRI HUBLI.

**Dr.J.G.Sutagatti**

HOD AND PROFESSOR

DEPT OF RADIO DIAGNOSIS

KMCRI HUBLI

All professors and teaching staff ,department of radiodiagnosis KMCRI HUBLI

THANK YOU